ORAL PATHOLOGY
Periapical Lesions

Lab 4

DR.NOOR

The factor which may affect lesions are:

- 1-the presence of open or closed pulpitis.
- 2-virulence of the involved microorganisms
- 3-extent of sclerosis of the dentinal tubules
- 4-competency of the host immune response of the individual.

1-Chronic apical periodontitis (periapic granuloma)

- The term periapical granuloma refers to a mass of chronically or sub acutely inflamed granulation tissue at the apex of a non vital tooth.
- The term is not totally accurate **because** the lesion does not show true granulomatous inflammation microscopically.
- The formation of the periapical granuloma represent **a defense reaction** secondary to the presence of microbial infection in the root canal with spread of related toxic products into the apical zone.

- In the early stages of infection, neutrophils predominate, and radiographic changes are not present, this phase of periapical inflammation is termed **acute periapical periodontitis**.
- The neutrophils release **prostaglandins** which activate osteoclasts to resorb the surrounding bone leading to detectable periapical radiolucency.
- With time, chronic inflammatory cells begin to dominate the host response.
- Mediators released by lymphocytes reduce further osteoclastic activity while also stimulating fibroblast and microvasculature

Radiographic features

chronic periapical granuloma

- Most lesions are discovered on routine radiographic examination which may show:
- 1-variable radiolucenies ranging from very small to 2 cm in diameter.
- 2-affected teeth typically reveal loss of the apical lamina dura.
- 3-the lesion may be circumscribed or ill def ned and may or may not demonstrate a surrounding radiopaque rim.
- 4- root resorption may be seen.
- The radiographic features are suggestive but not diagnostic.

External resorption. Extensive irregular destruction of both roots of the mandibular second molar associated with chronic periodontitis.

Periapical Granuloma

Figure 3-16 • **Periapical granuloma.** Well-defined radiolucency associated with the apex of the maxillary first bicuspid. (Courtesy of Dr. Frank Beylotte.)

[redacted]

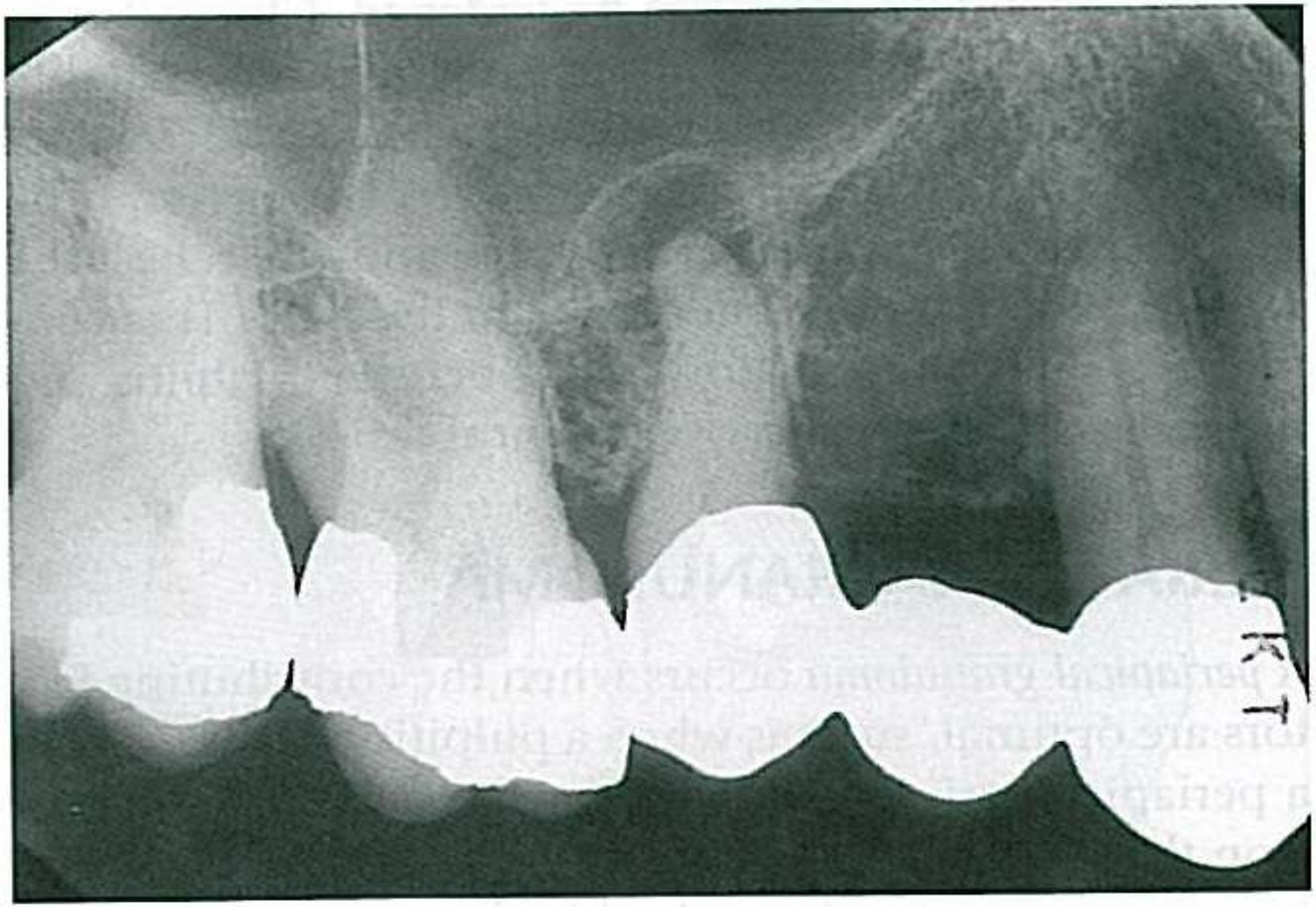

Periapical granuloma. Radiograph of a periapical granuloma with a prominently corticated outline of the interface with normal bone that is in continuity with the lamina dura of the associated tooth.

HISTOPATHOLOGICAL FEATURES

- Periapical granulomas consist of an inflamed granulation tissue surrounded by fibrous connective tissue wall.
- The central part of the lesion contains macrophages with foamy cytoplasm caused by the phagocytosis of cholesterol.

HISTOPATHOLOGICAL FEATURES

- When numerous plasma cells are present, scattered eosinophilic globules of gamma globulin **(Russell bodies)** may be seen.
- A frequent f ṅding is the presence of irregular **islands of epithelium**, a result of prolonged, mild stimulation of the rest malassez, which are remnants of the Hertwig root sheath.

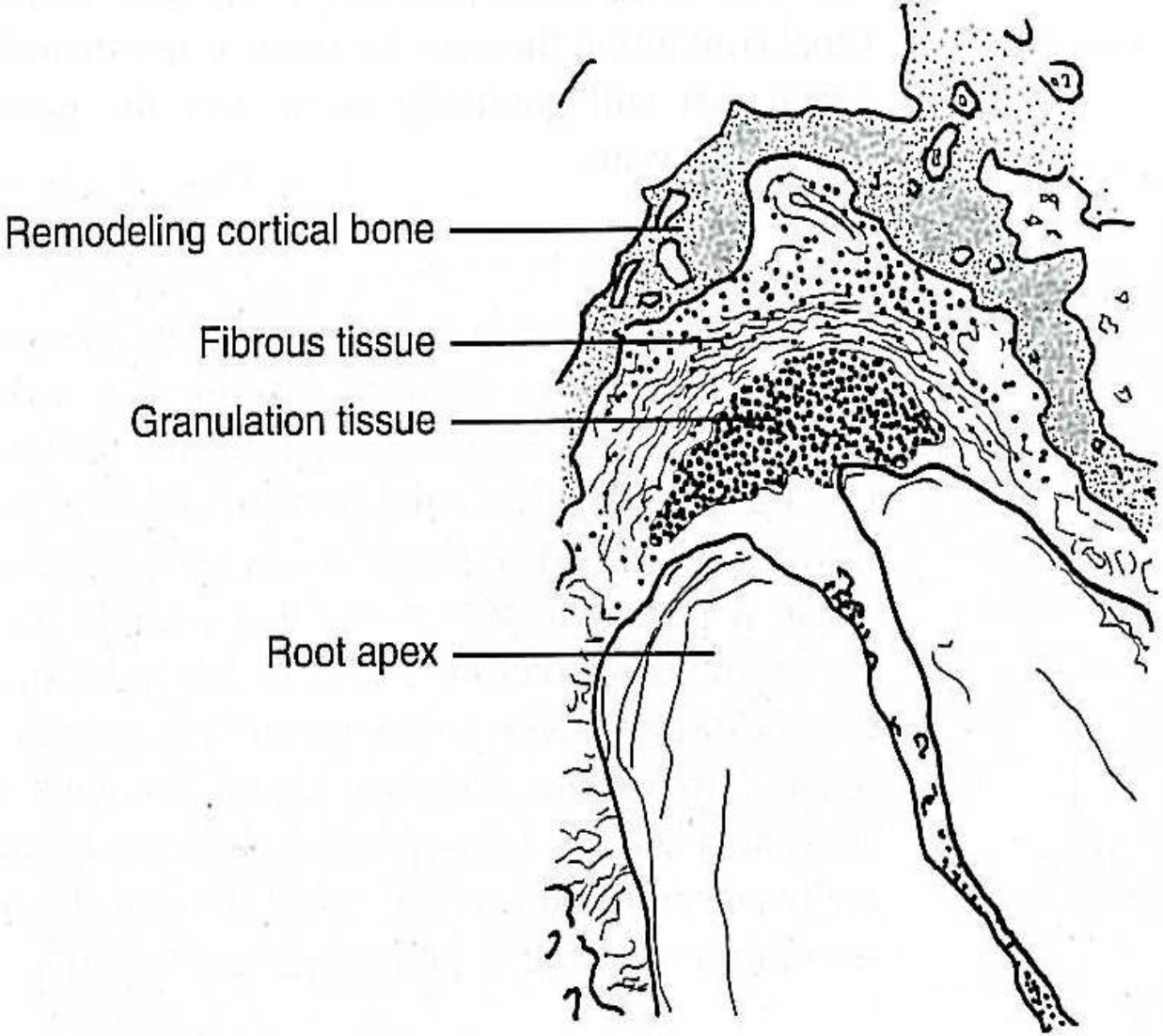

Periapical granuloma. Microscopic appearance of the early stage of granuloma development, exhibiting granulation tissue at the apical foramen surrounded by fibrous tissue and an outer zone of cortical bone.

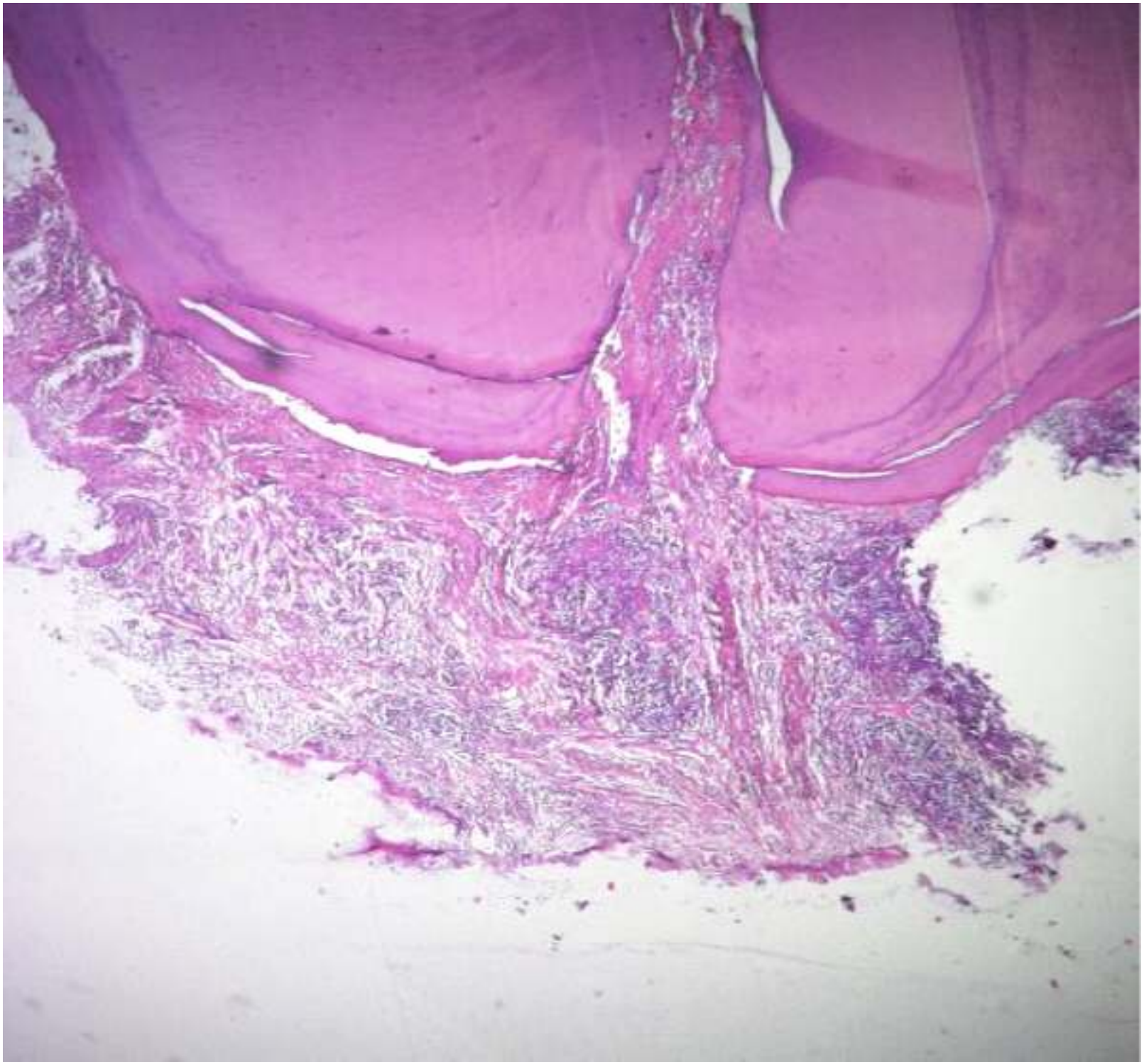

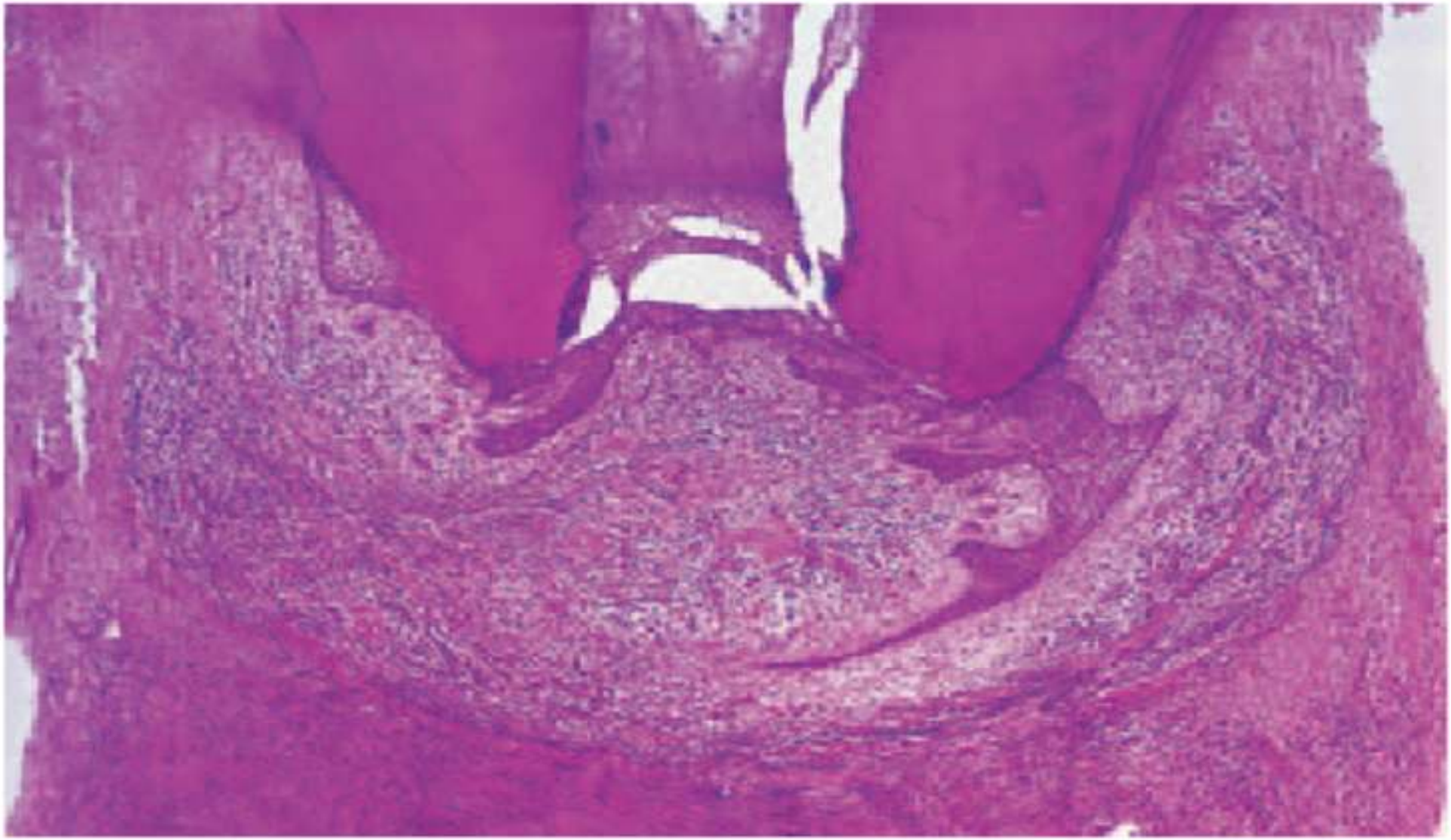

Fig. 4.22 Epithelial proliferation in an apical granuloma. Inflammation induces proliferation of odontogenic epithelium in rests of Malassez. This change may lead to cyst formation (Ch. 7).

Sequelae:-

- Periapical granuloma may continue to enlarge with continued bone resorption.
- Acute exacerbation to an **acute periapical periodontitis.**
- A suppuration to form **an acute periapical abscess.**
- Formation of a **radicular cyst.**
- Low grade irritation may cause **osteosclerosis** (bone apposition) or cementum apposition (**hypercementosis**).

2-Acute periapical periodontitis

Histopathological findings

- Vascular dilatation , an exudates of neutrophils, and oedema, in the periodontal ligament situated in the confined space between the root apex and the alveolar bone.

Clinically

- Pain is intense when external pressure is applied to the tooth, as the pressure is transmitted through the fluid exudate to the sensory nerve endings.
- Even light load may be sufficient to induce pain, as the fluid is not compressible, **the tooth feels elevated in its socket.**

Radiographical findings

The findings are often normal as there is generally insufficient time for bone resorption to occur between the time of injury to the periodontal ligament and the onset of symptoms.

If radiological changes are present, they consist of slight widening of periodontal ligament and the lamina dura around the

Sequela and prognosis

The inflammation may be transient if it is due to acute trauma rather than infection and the condition seen resolves.

If the irritant persist the inflammation becomes chronic and may be associated with resorption of the surrounding bone. Suppuration may occur associated with necrosis and bacterial infection with continued exudation of neutrophils leading to **abscess** formation, called **acute periapical abscess.**

Drainage pathways of acute periapical infections. The location of the various points of drainage is determined by the anatomic location of the root apex. Common locations are *(1)* surface of gingiva (parulis), *(2)* palate (palatal abscess), *(3)* maxillary sinus, *(4)* soft tissue spaces superior (maxilla) and inferior (mandible) to buccinator muscle (cellulitis), and *(5)* floor of the mouth (Ludwig angina).

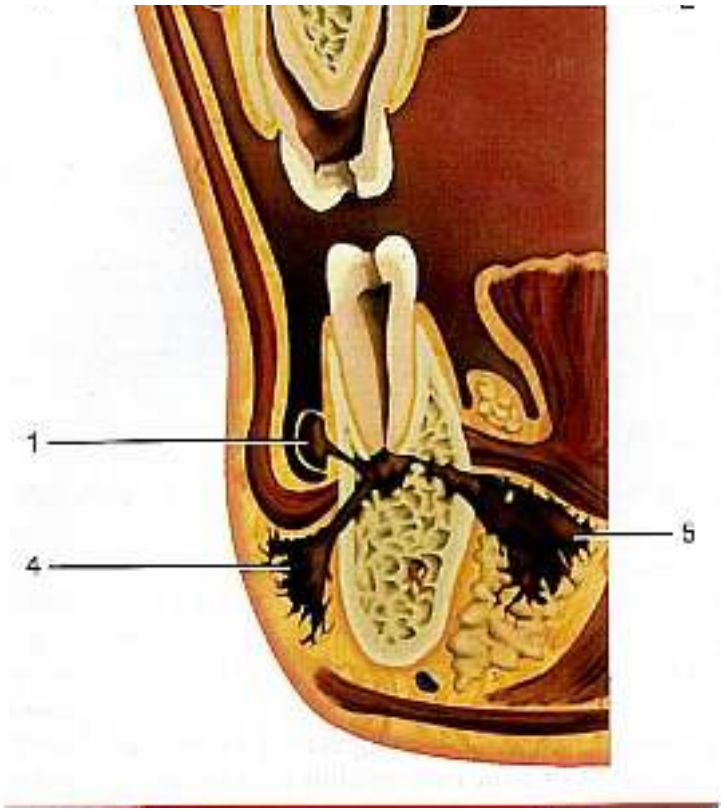

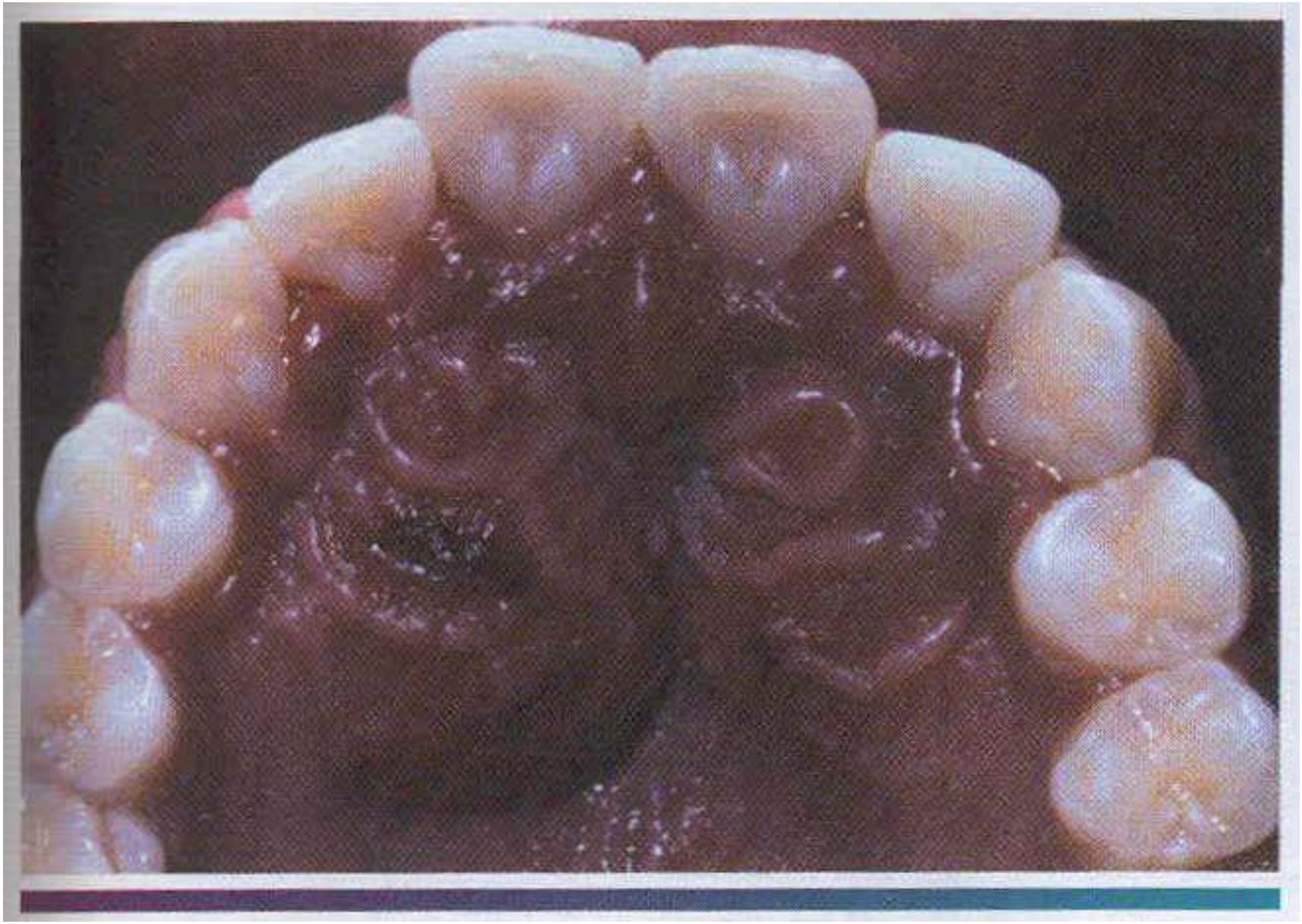

Periapical abscess.

Bilateral soft-tissue swelling of the anterior palate.

Radiographic features

- Abscess may demonstrate a thickening of apical periodontal ligament, an ill def ined radiolucency. However, often **no** appreciable alterations can be detected because insuf ficient time has occurred for significant bone destruction.

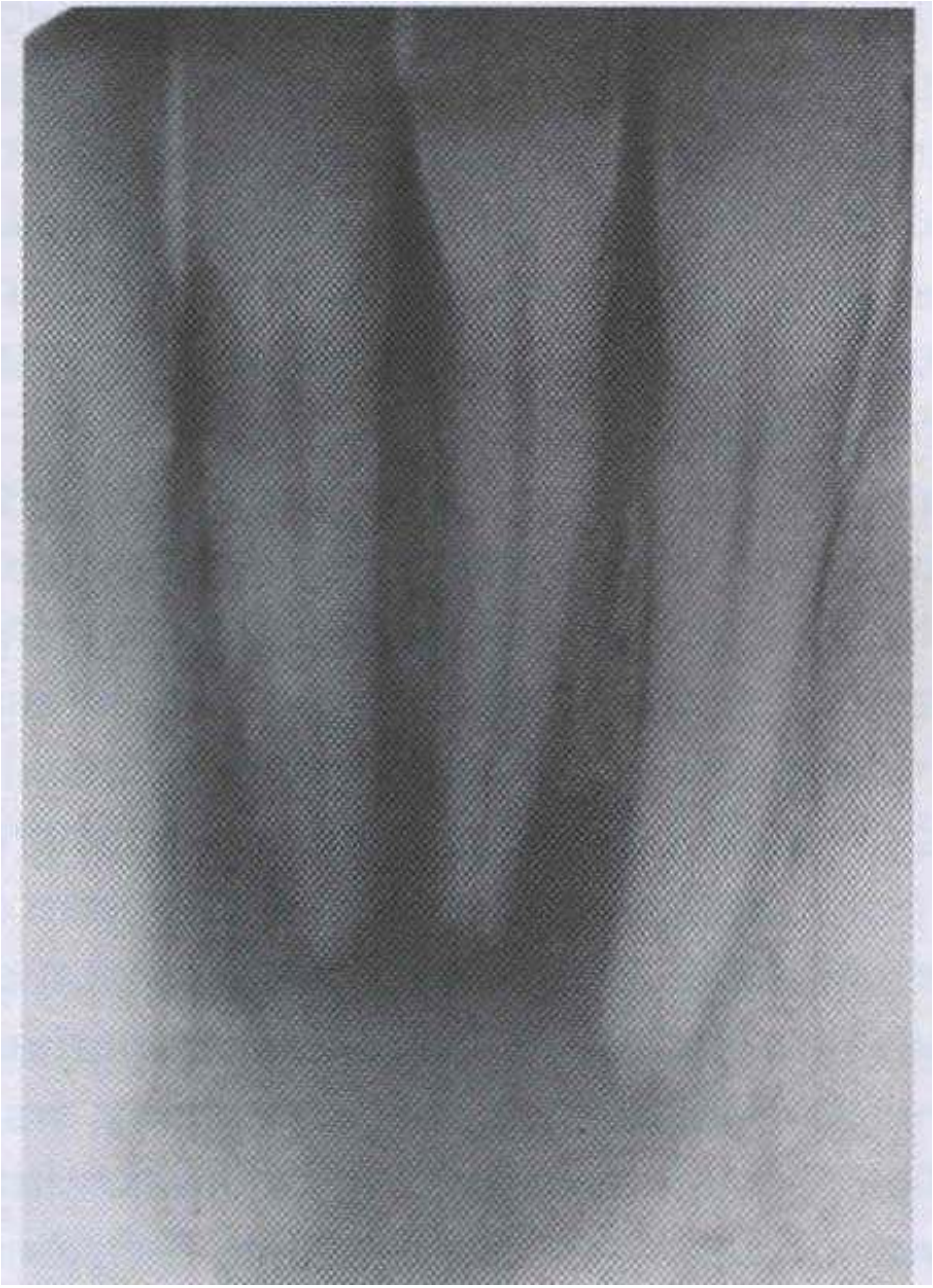

Periapical abscess, periapical radiolucency associated with the nonvital mandibular lateral incisor.

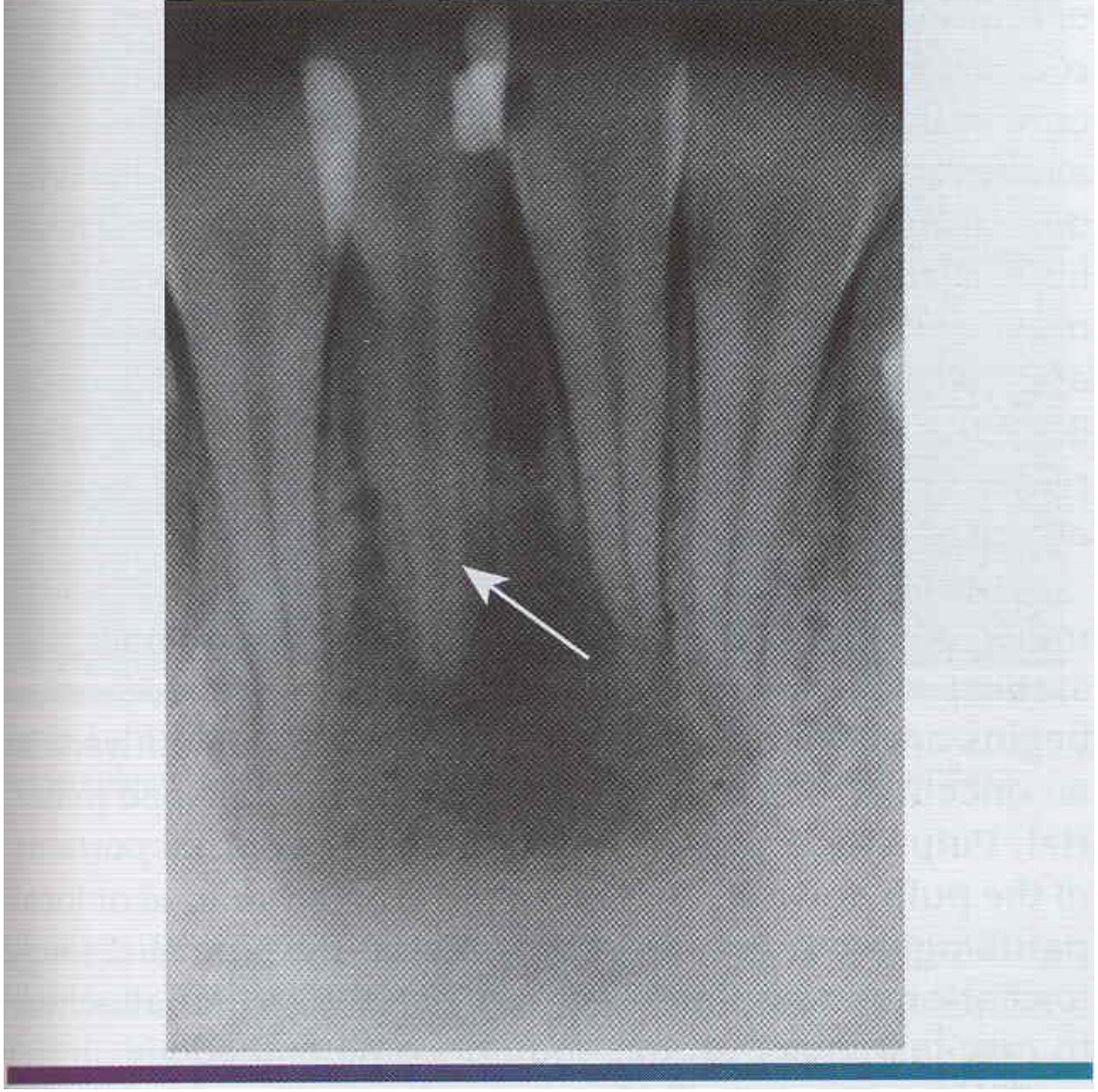

Physiologic secondary dentin. Periapical abscess with all four teeth non responsive to electric pulp testing. decreased deposition of physiologic secondary dent in on the right central incisor *(arrow) delineated the origin of the infection;* endodontic treatment of this tooth resolved the lesion.

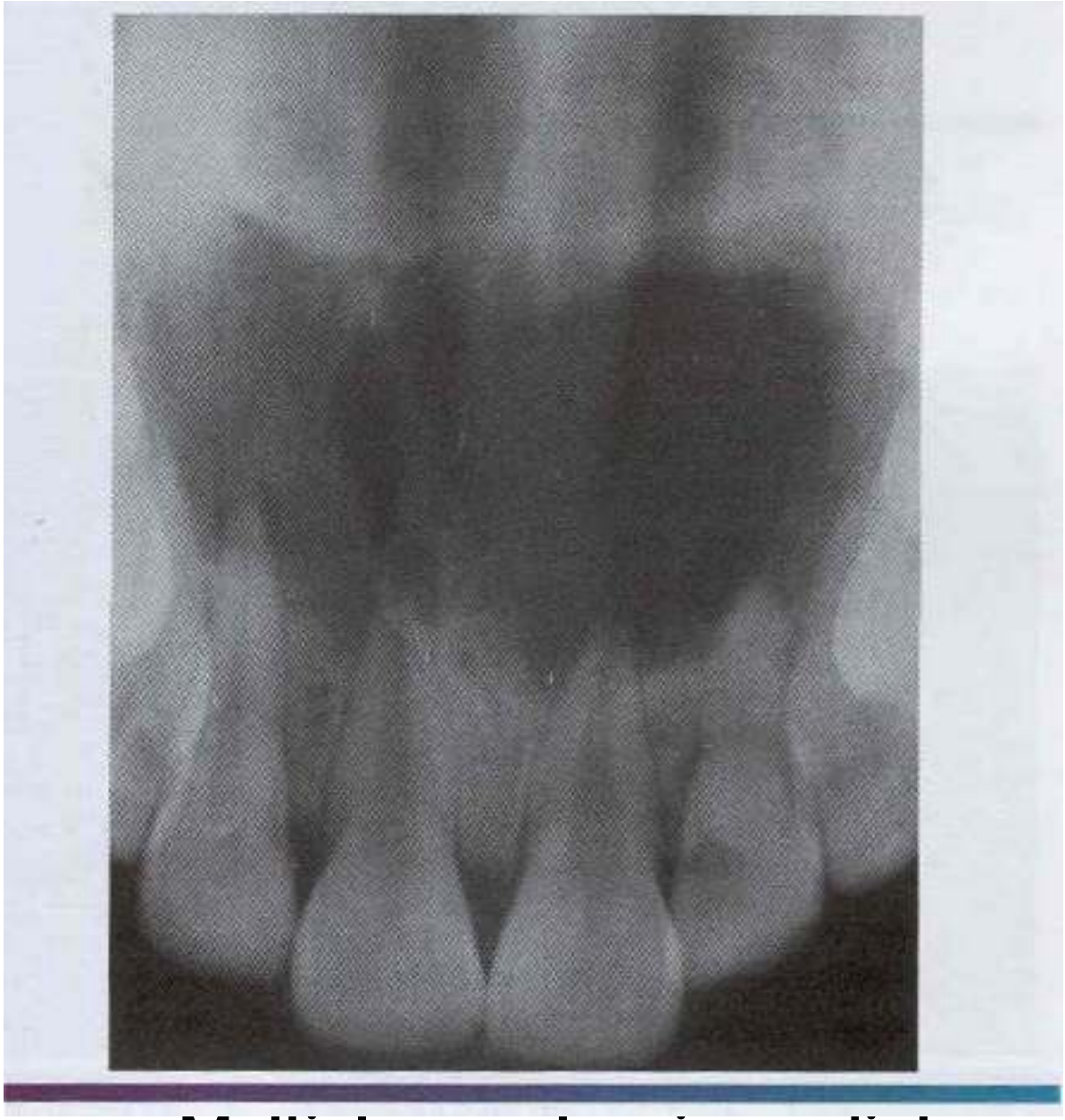

Periapical abscess. Multiple, overlapping radiolucencies of the anterior maxilla are present. All four maxillary incisors exhibit pulpal necrosis.

Histopathology

- A **periapical abscess** appears as a zone of liquefaction, composed of proteinaceous exudates, necrotic tissue and viable and dead neutrophils, (pus).
- Adjacent tissues containing dilated vessels and a neutrophilic infiltrate surrounds the area of liquifactive necrosis.

Sequelae

- 1-with progression, the abscess spreads along the path of least resistance and discharge into the oral cavity through **a sinus tract** following local penetration of overlying periosteium and mucosa.
- On other occasions the pus may accumulate beneath the mucosa and the patient may complain of a swelling at the intraoral opening of a sinus tract, which is a mass of subacutely inflamed granulation tissue known as **parulis ((Gum boil)).**

A

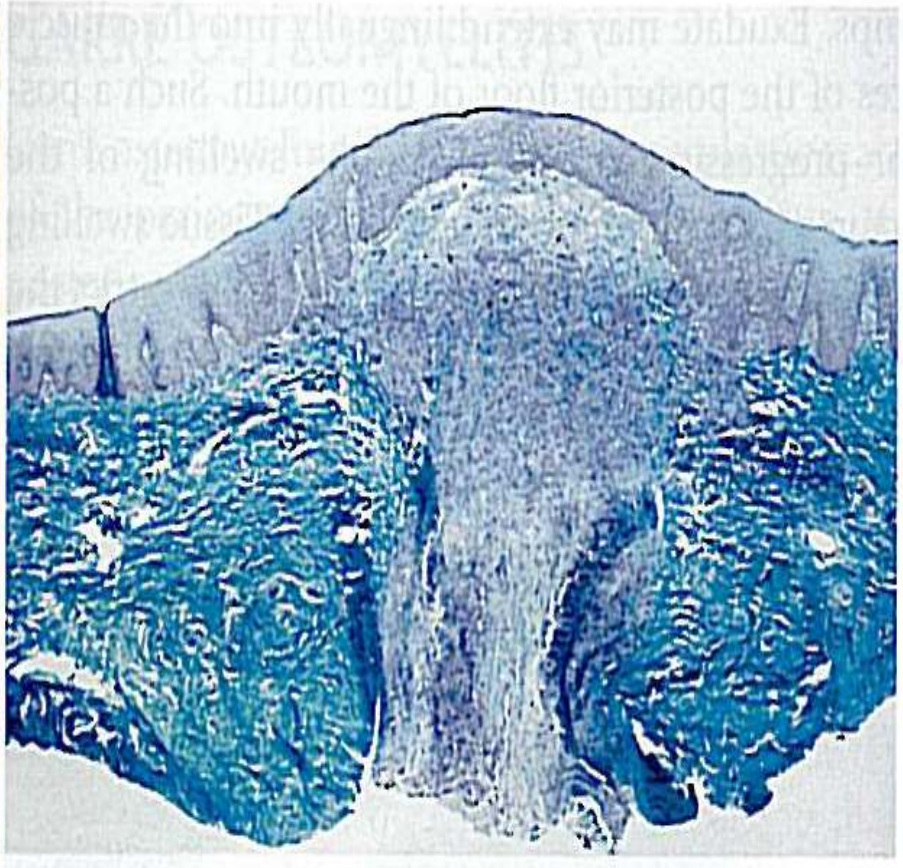

B

Parulis. A, Patient with a small nodule represents the opening of a draining sinus tract on the gingiva adjacent to a nonvital left mandibular cuspid. **B,** Microscopic appearance of a gingival nodular swelling, demonstrating the central core of purulent exudate (sinus tract) exerting pressure beneath the epithelium that is near the point of rupture (Trichrome stain).

- 2- may extend through the medullary spaces away from the apical area, resulting in **Osteomyelitis**
- 3-dental abscesses may discharge through the **skin** and drain via a cutaneous sinus.
- 4-periapical infection occasionally spread the **blood** stream and result in systemic symptoms such as fever, lymphadenopathy and malaise.
- 5-it may spread diffusely through facial planes of the soft tissues. This acute and edematous spread of an acute inflammatory process is termed **Cellulitis.**

Palatal abscess. A large fluctuant swelling of the palate caused by the drainage of purulent exudate into the submucosal tissue from an apical area of nonvital premolars.

- **Cellulitis** is a misnomer, because the process is not an inf ammation of the cells but an acute condition in which purulent forms of bacteria, involve the facial and perioral mucosa.
- Occasionally the exudates tracks onto the palate, producing a large swelling, when a periapical abscess erodes into the maxillary sinus, destroying the intervening bone and lining, and when offending tooth is extracted, a communication between the f bor of the maxillary sinus and the oral cavity may result. **(oroantral fistula).**

Oroantral fistula. An open communication between the maxillary sinus (antrum) and the oral cavity is present on the edentulous alveolar ridge after the extraction of a molar with a long-standing periapical lesion that involved the sinus floor.

- Extension of the pus lingually into the tissue spaces of the posterior f bor of the mouth may result in swelling of the structures around the epiglottis which is a **life threatening**, as it restrict the airway and may cause suffocation.
- Cellulitis of this area ((submental , submandibular and sublingual spaces)) is called **Ludwig's angina.**

- Another serious complication is the extension of the exudates into the maxillary cavernous sinus area, resulting in **thrombophlebitis**. From this location fatal forms of **brain abscess or acute meningitis** are possible unless rapid intervention is undertaken.

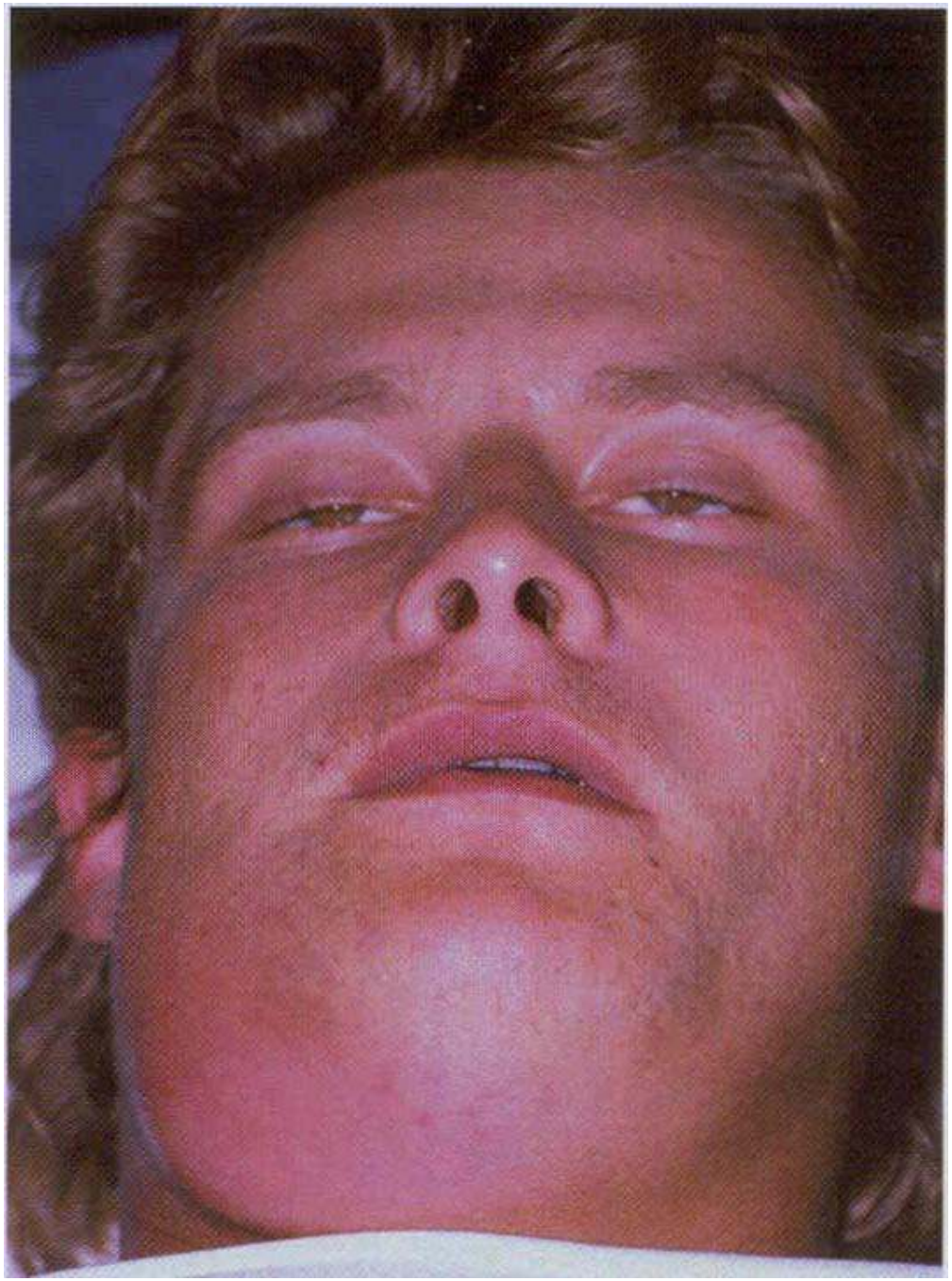

Ludwig's angina.
Soft-tissue swelling of the right submandibular region.

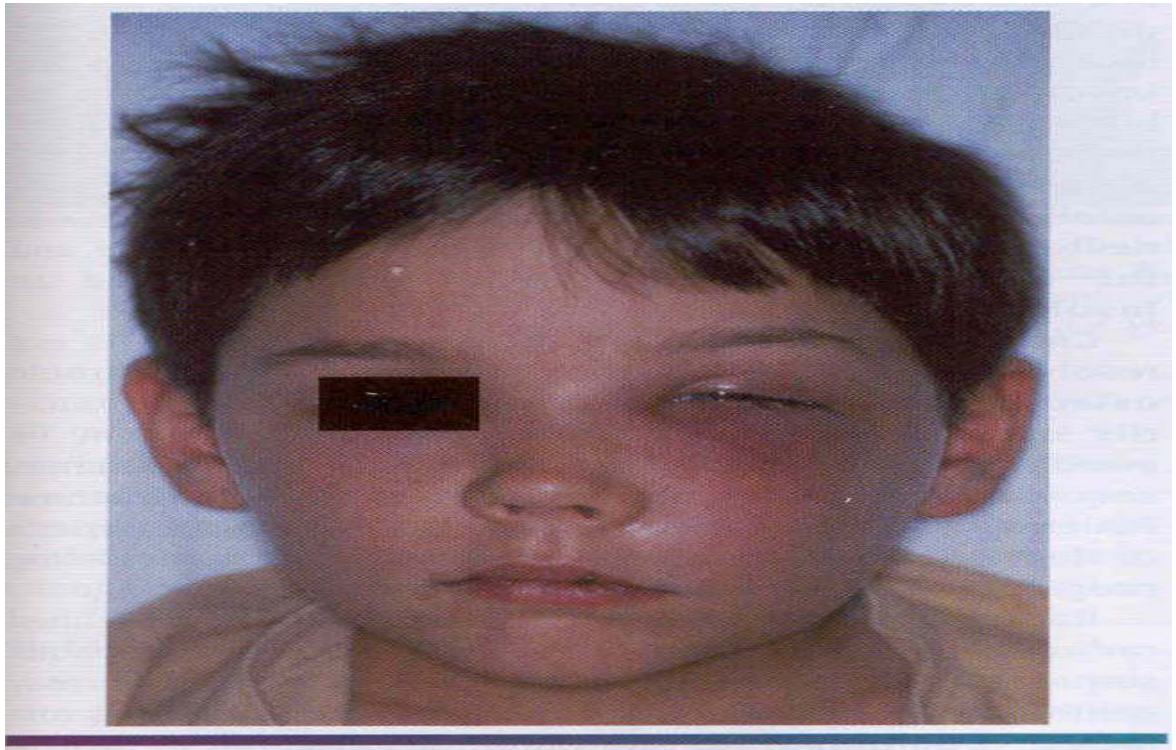

Cellulitis involving canine space :

Erythematous and edematous enlargement of the left side of the face with involvement of the eyelids and conjunctiva. Patients with odontogenic infections involving the canine space are at <u>risk for cavernous sinus thrombosis</u>.

4-Radicular cyst

Clinical and radiographical features

- Apical radicular cyst are the most common cystic lesions in the jaws and are always associated with apices of non vital teeth .
- However the majority of radicular cyst do not grow to large dimensions. The expansion of the alveolar bone is due to deposition of successive layers of new bone by overlying periosteum.

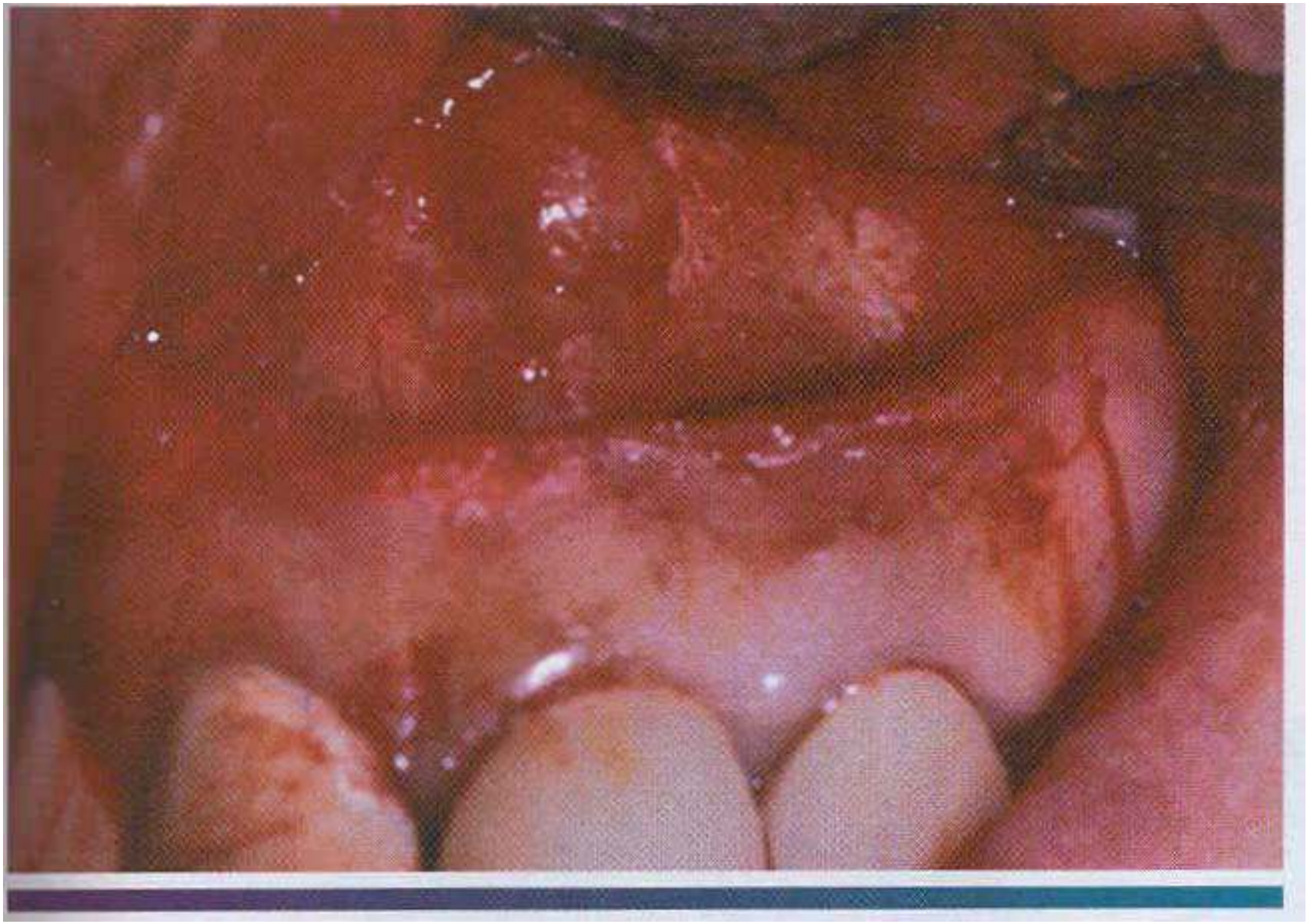

Periapical cyst. The clinically significant cyst. Which was not appreciated
fully on the radiograph. (Courtesyof dr. Brian blocher.)

- As the cyst enlarge and cause bone resorption centrally. Increments of new subperiosteal bone are laid down to maintain the integrity of the cortex. Producing a bony hard expansion.
- However the rates of expansion tens to outstrip the rate of subperiosteal deposition. Leading to progressive thinning of the cortex which can be deformed on palpation producing the clinical signs of **((oil can bottoming)) and ((egg shell crackling)).**
- Eventually the cyst may perforate the cortex and present as a bluish fluctuant submucosal swelling.
- The rate of expansion of radicular cyst has been estimated

- **Radiographically** the **apical radicular cyst** presents as a round or avoid radiolucency at the root apex. The lesion is often well circumscribed and may be surrounded by peripheral radio-opaque margins continues with lamina dura of the involved tooth.
- The **residual cyst** is other varieties a radicular cyst that has remained in the jaw and failed to resolve following extraction of the involved tooth. About 20% of radicular cyst are of this type

- The **lateral radicular cyst** type is very un common and arises as a result of extension of inf lammation from the pulp to into the lateral periodontal along the **lateral root canal**

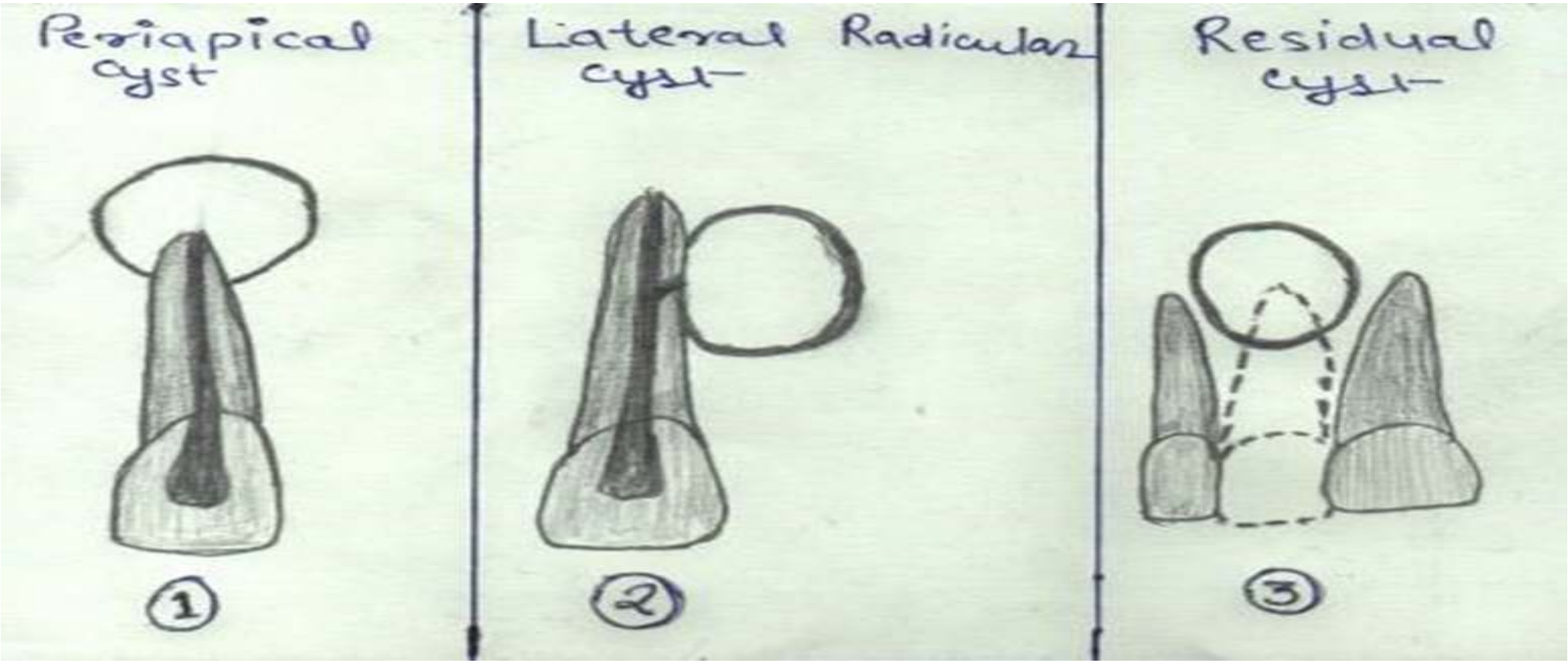

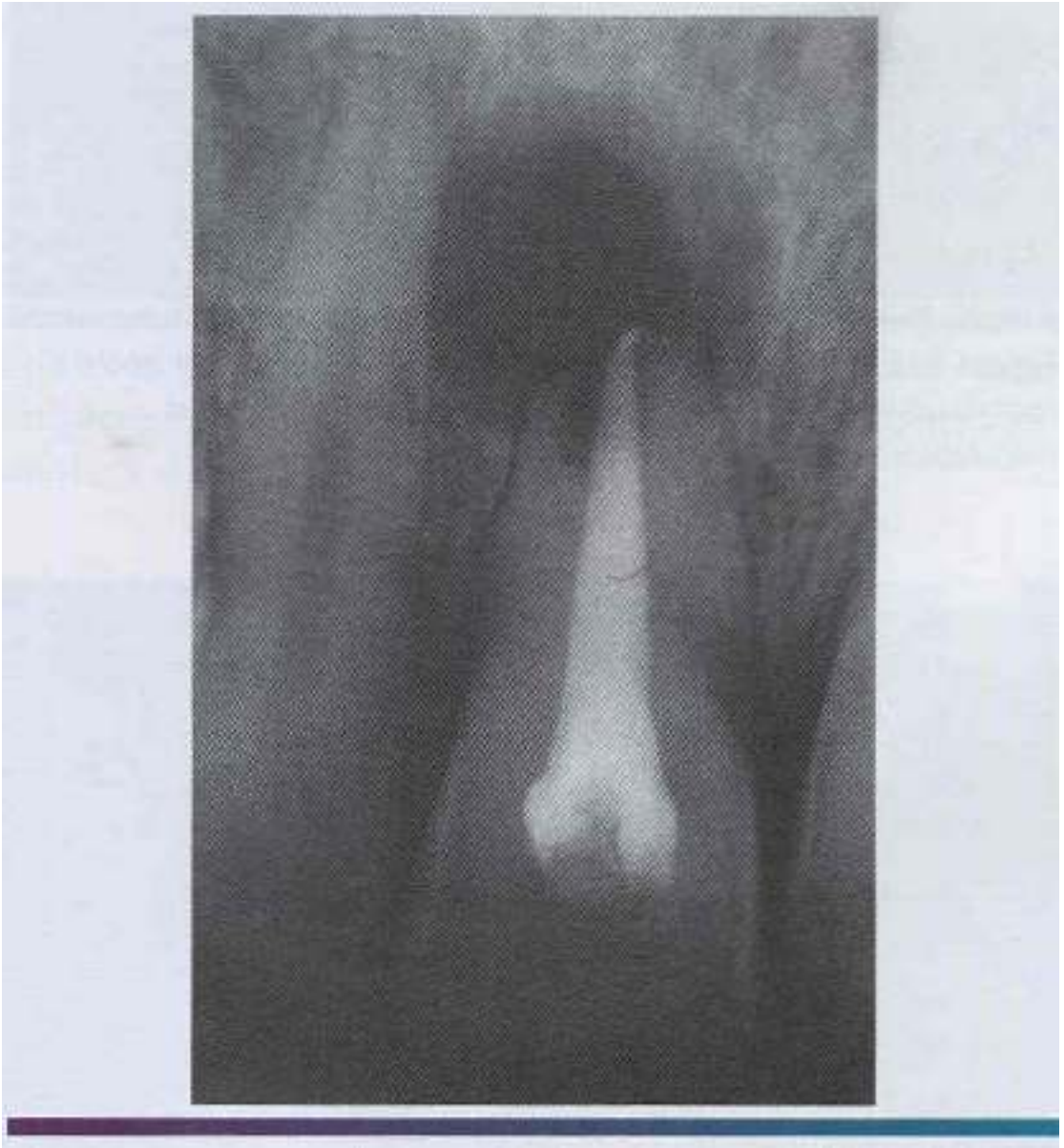

Periapical cyst. Radiolucency associated with the maxillary central incisor, which exhibits significant root resorption.

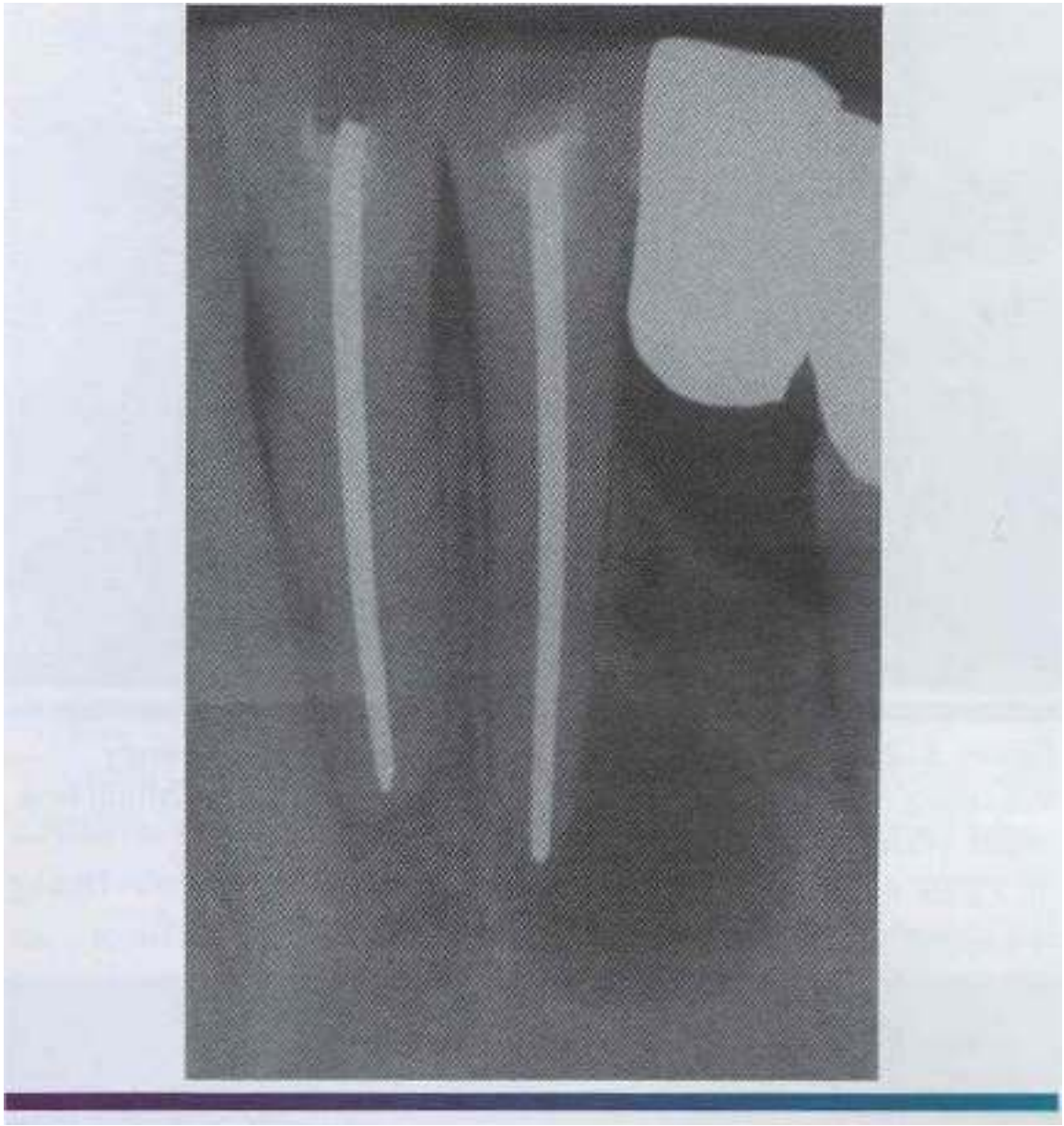

Periapical cyst.

Well-circumscribed radiolucency intimately associated with the apex of the mandibular central incisor. Note the loss of lamina dura in the area of the lesion.

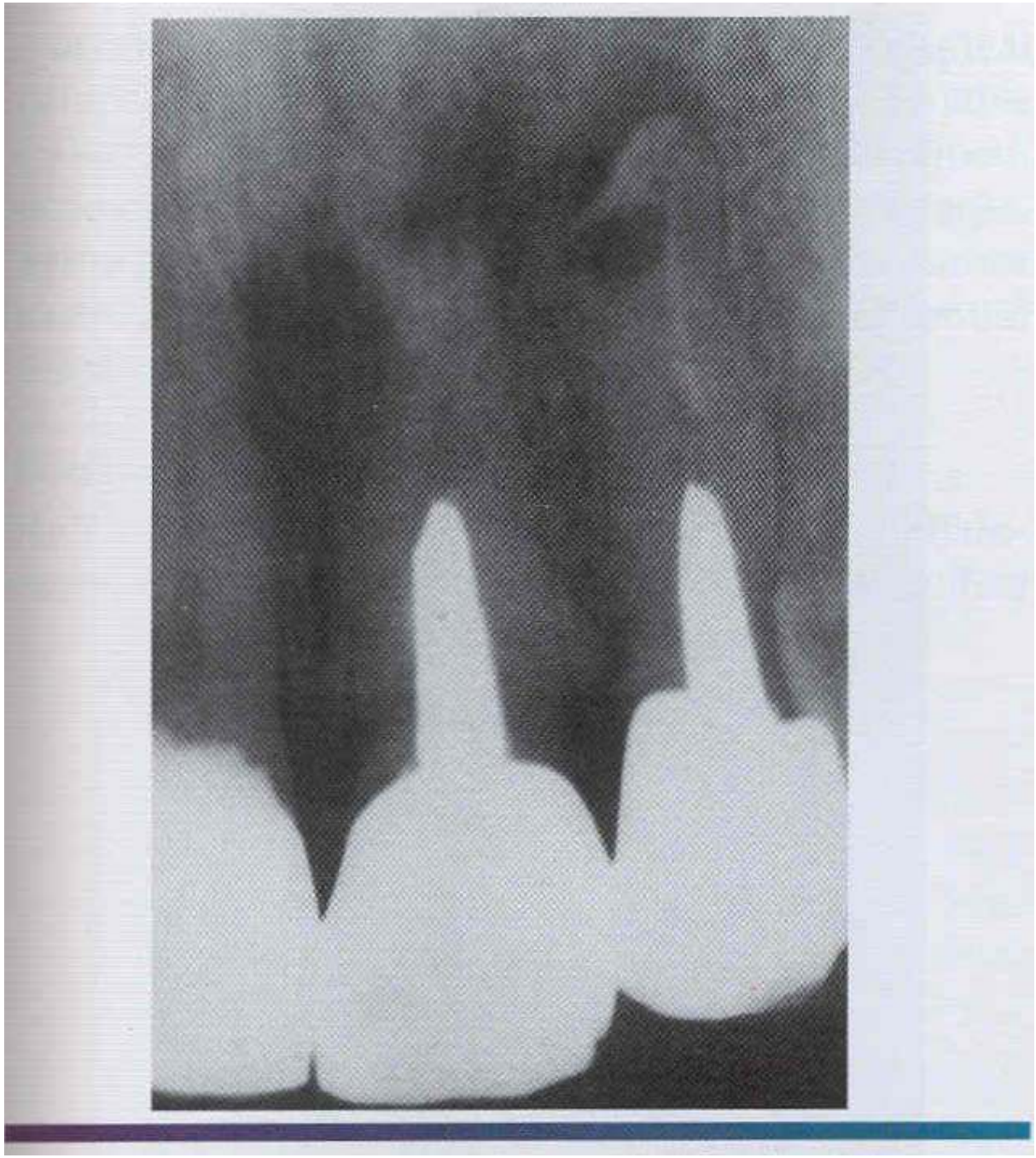

Periapical cyst. Discrete. Ill-defined radiolucency associated with the maxillary left central incisor.

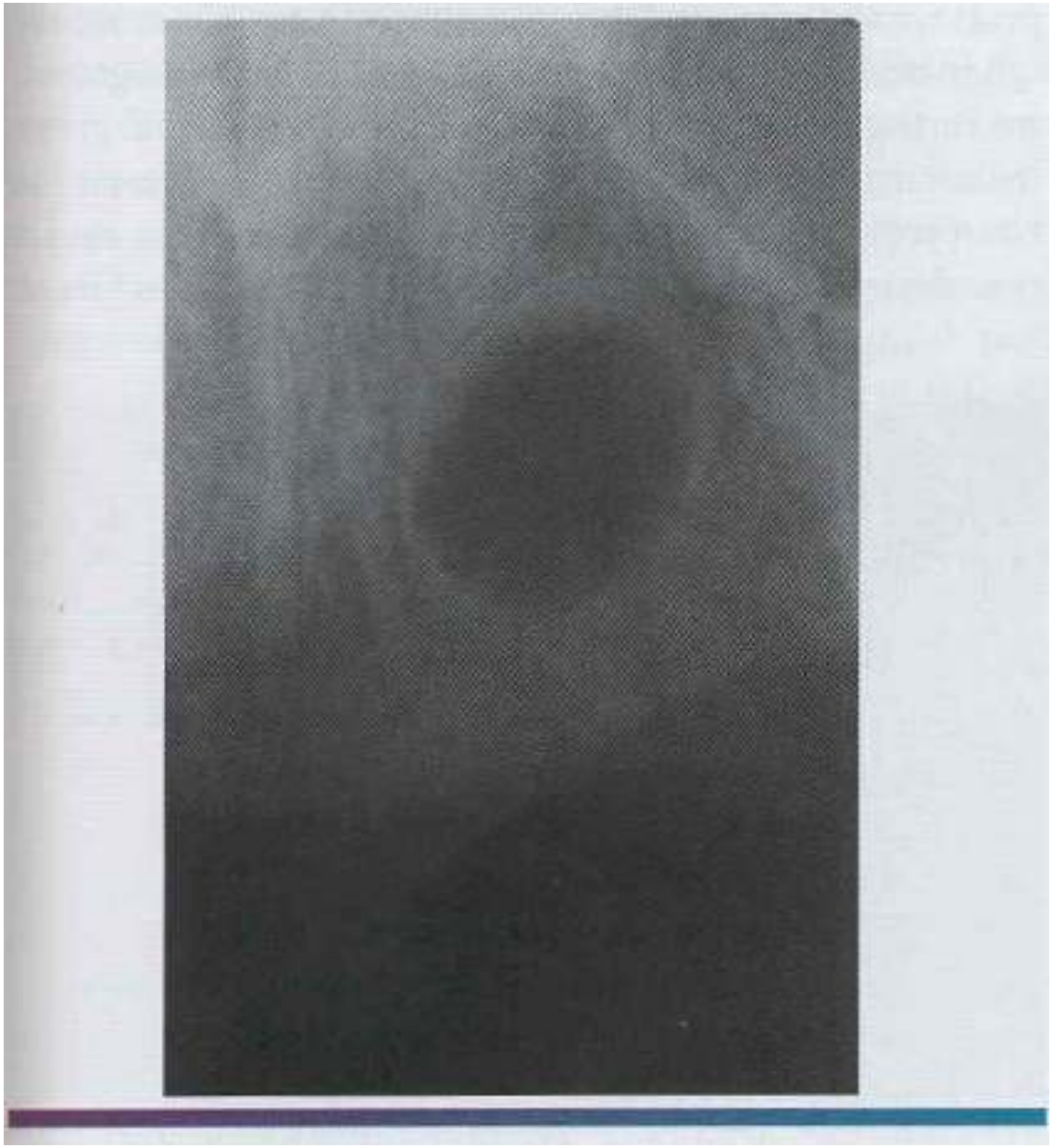

Residual periapical cyst .
persistent radiolucency of the mandibular body at site of previous tooth extraction.

Pathogenesis

- Radicular cyst arise from proliferation of **rest of malassez** within chronic periapical granulomas but not all granulomas progress to cyst.
- It is assumed that the environment within chronically inflamed granuloma is **rich in cytokines including growth factors,** Stimulates the rate of malassez to proliferate strands and sheets of squamous epithelium derived from proliferation of the rest are common finding in the periapical granulomas.

- Two main **mechanism** formation of an epithelial lined cyst cavity within granuloma have been proposed:
- **1-**Degeneration and death of central cells within a proliferating mass of epithelium. Epithelium is a **vesicular** and transport of metabolites and gaseous exchange occur by diffusion.
- It argued that when the mass proliferating epithelium within granuloma reaches a critical size. The central cells furthers away from the surrounding vascular bed. **Degenerate and die**, the micro cyst so formed then continues to expand .

- 2-Degeneration and liquifactive necrosis of granulation tissue.
- It is suggested that areas of granulation tissue within the granuloma may undergo necrosis due to **enclavement** by proliferating strands of epithelium or to release toxic products from a dead pulp or from infecting organism.
- Epithelial proliferation to surrounded such an area of necrosis result in the formation of cyst.

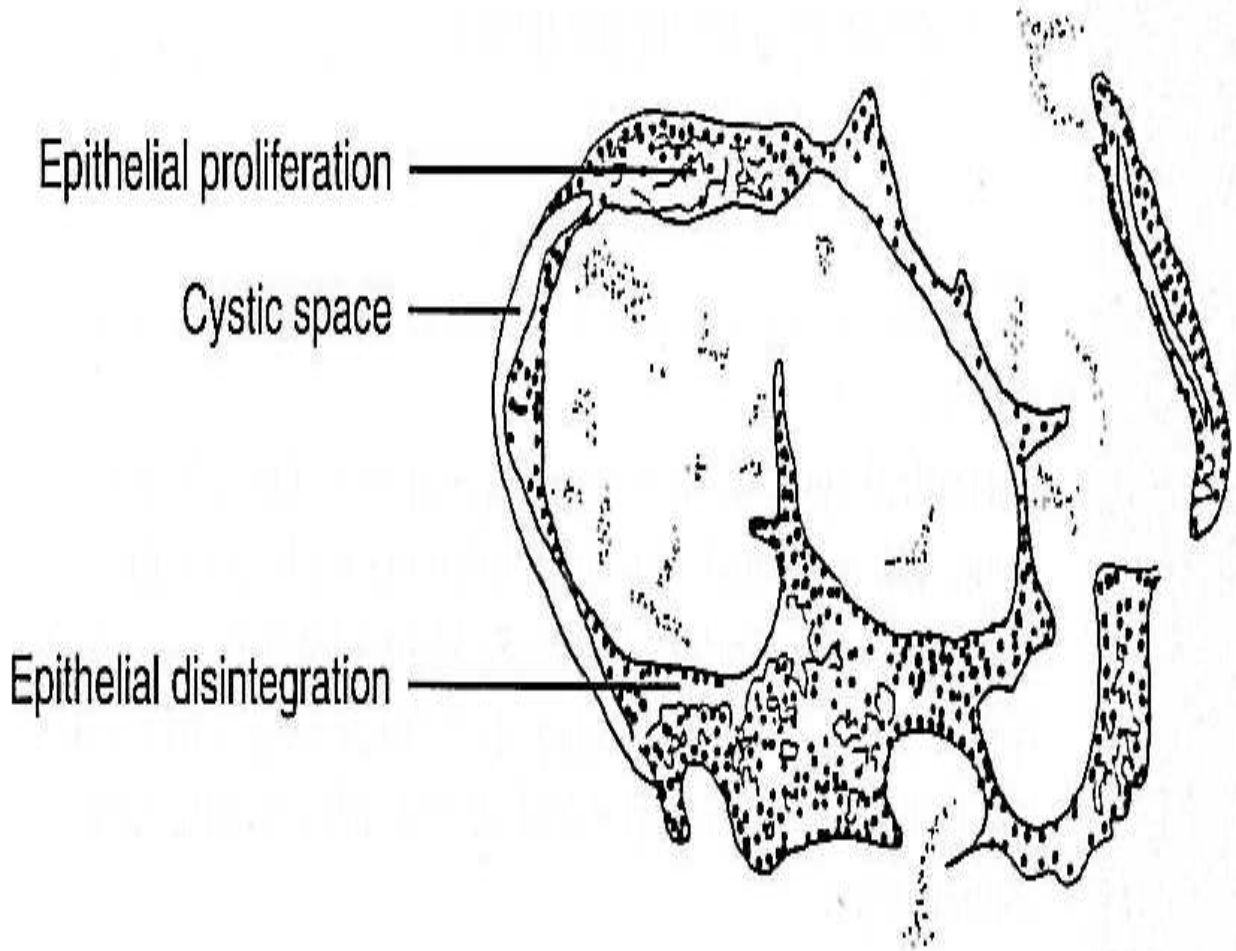

[redacted]

Periapical cyst. Microscopic appearance of developing cystic lining from proliferating rests of Malassez stimulated by the chronic inflammation of the preceding periapical granuloma.

Histopathology

- Radicular cyst are lined wholly or impart by know keratinized stratified squamous epithelium supported by a chronically inflamed fibrous tissue capsule.
- **In a newly formed cyst** the epithelial lining is irregular and may vary considerably in thickness.
- Hyperplasia is a prominent feature in long anastomosing cords of epithelium forming complex arcades extending into the surrounding capsule.

- In **established cyst** the epithelial lining is more regular in appearance and fairly even thickness breaks in the linings epithelial discontinuities are common.
- **Metaplasia** of epithelial lining may give rise to a mucus cell, Found in about 40% of radicular cyst lining and more rarely Ciliated cells and area of respiratory types epithelium.
- the lining epithelium may demonstrate linear or arch-shaped calcifications known as **Rushton bodies** They appear to have no clinical or diagnostic significant and they origin is unknown

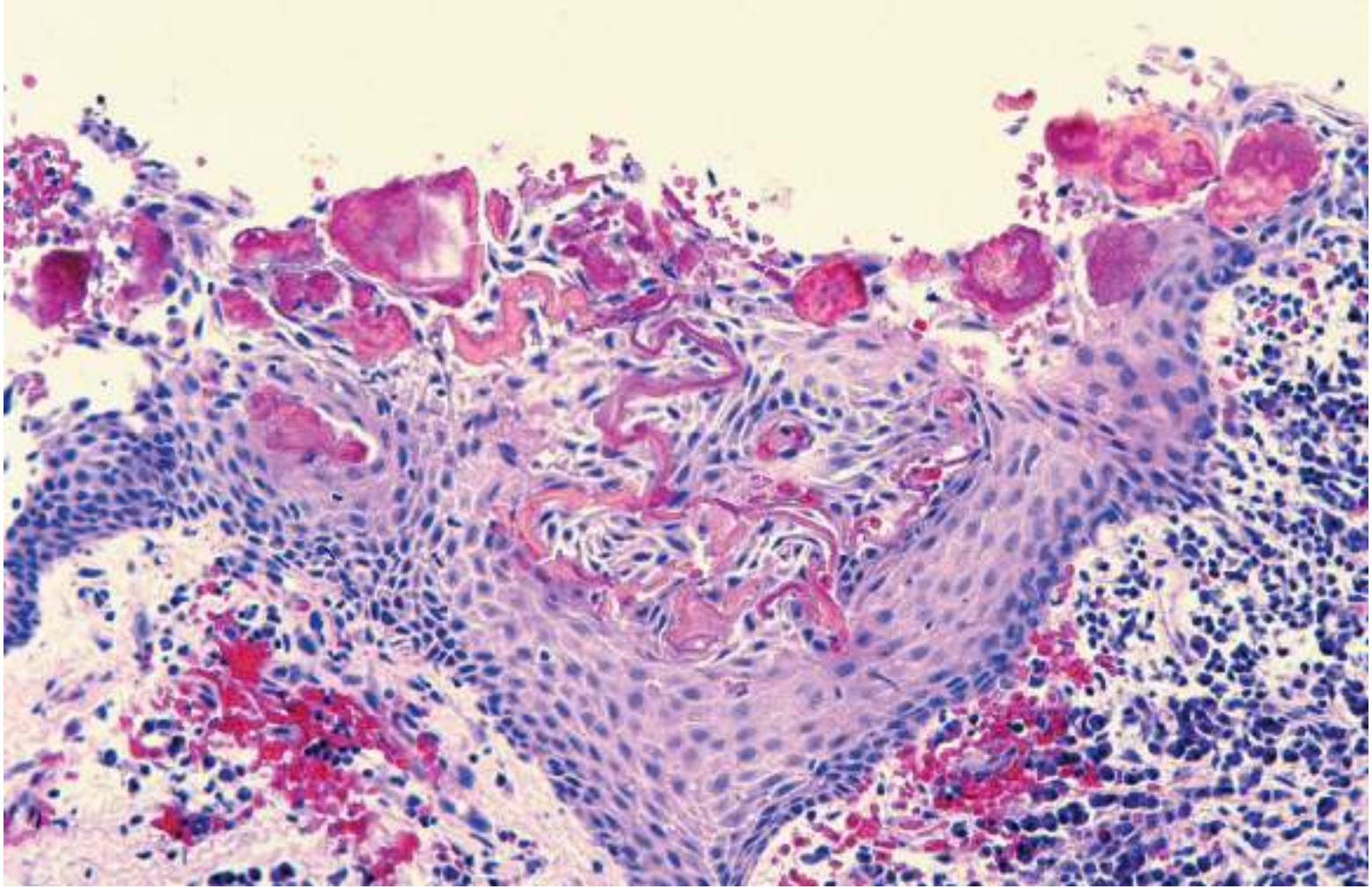

Periapical Cyst.

Squamous epithelial cyst lining exhibiting
numerous irregular and curvilinear Rushton bodies.

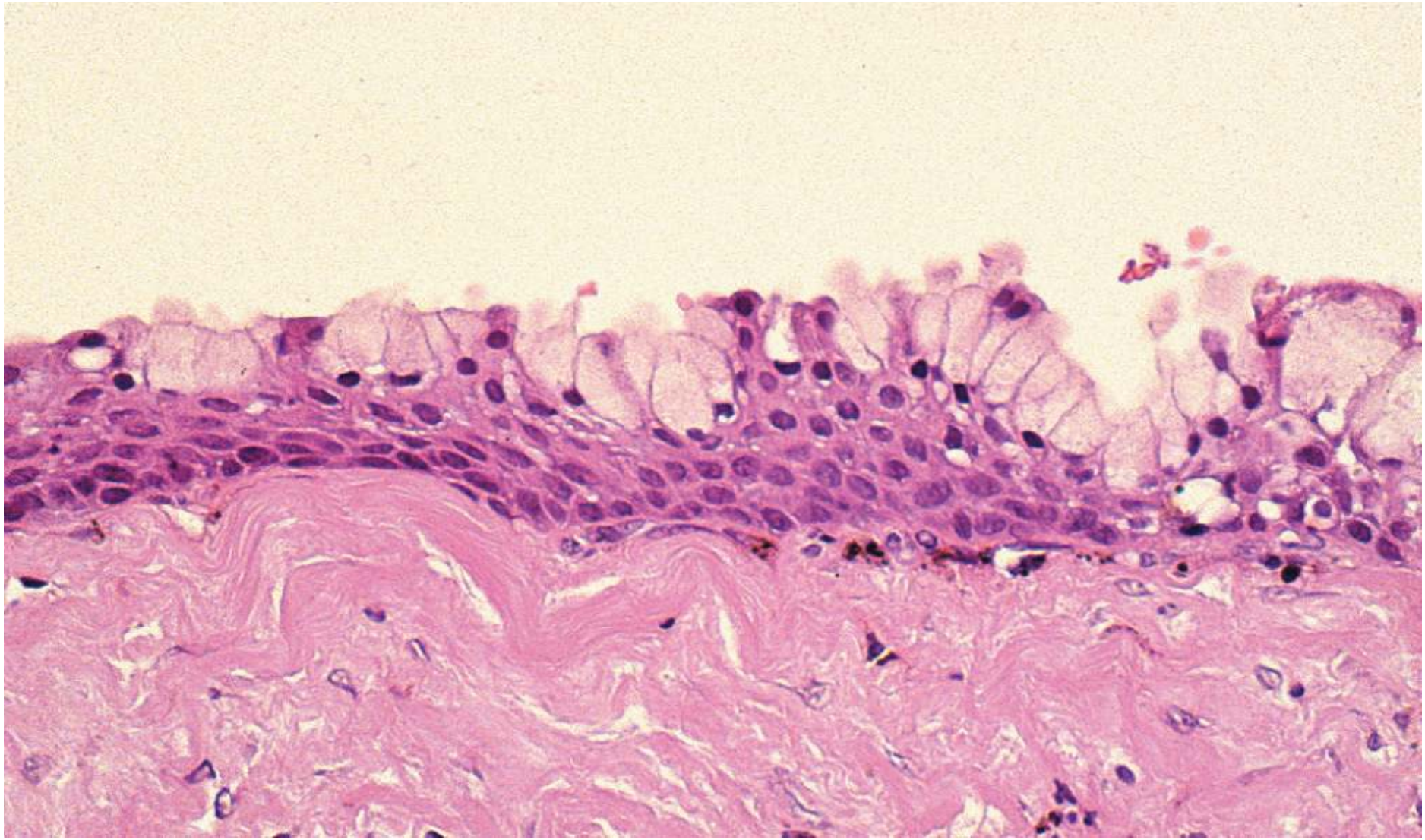

Periapical Cyst.
Stratified squamous epithelial lining containing numerous mucous cells.

- Deposits of cholesterol crystals are common within the capsules of many radicular cysts
- within time the connective tissue capsule tends to become more fibrous and less vascular and there is reduction in the density of inflammatory cell infiltration, myofibroblast in capsule may help to constrain the tendency of the cyst to expand

- As a periapical granulomas the cholesterol probably derived from the breakdown of red blood cells as a result of hemorrhage in the cyst capsule and deposits of hemosiderin are commonly associated with the clefts.
- Occasionally, the walls of inf ammatory cysts will contain scattered hyaline bodies
- These bodies appear as small circumscribed pools of eosinophilic material that exhibits a corrugated periphery of condensed collagen often surrounded by lymphocytes and multinucleated giant cells

A

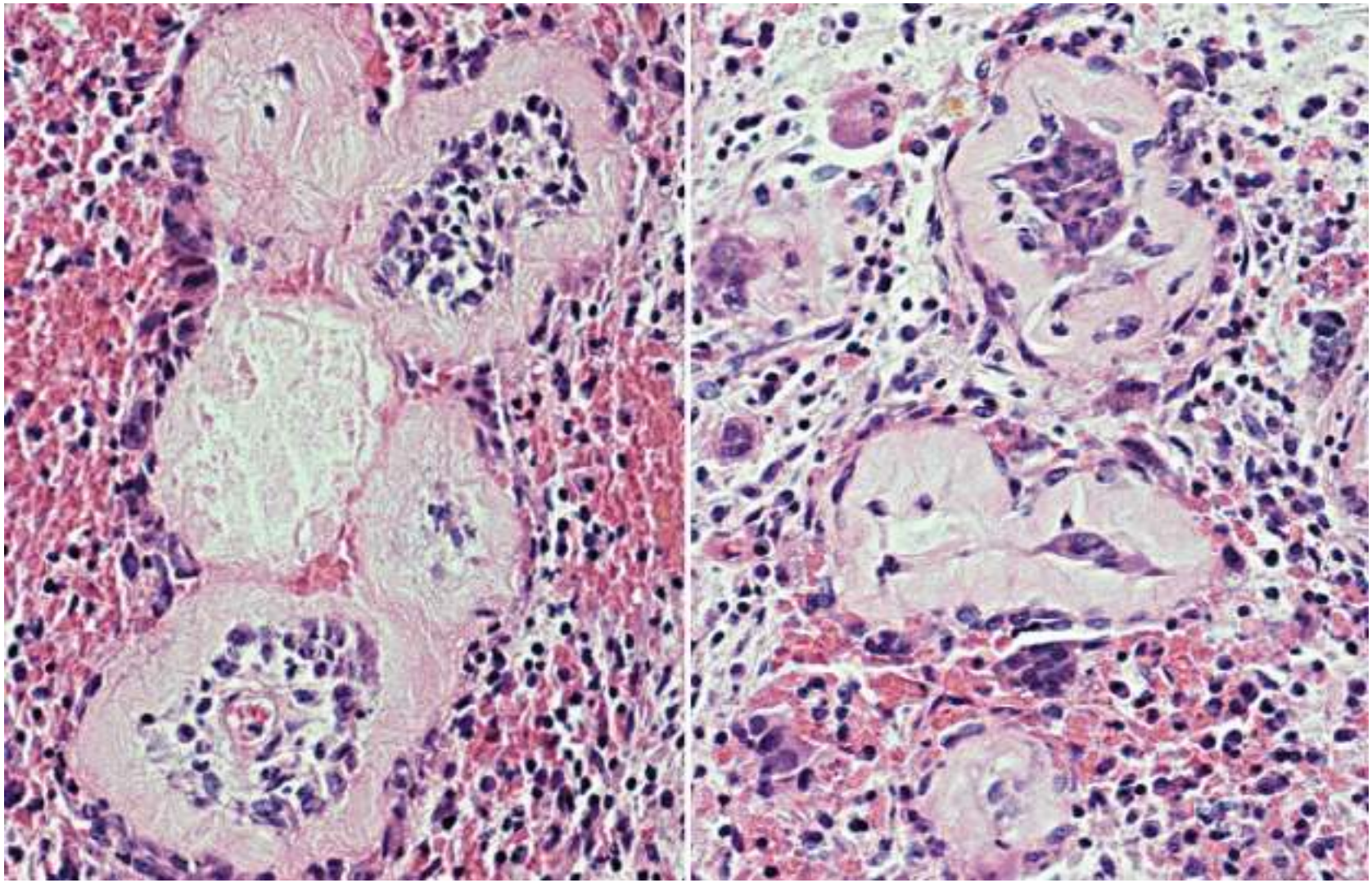

B

Hyaline Bodies.

A, Multiple hyaline bodies appearing a corrugated collagenous rings surrounding lymphocytes and plasma cells; note early hyaline body filled with serum.
B, Multiple hyaline bodies with numerous multinucleated giant cells within and around the
corrugated collagenous rings.

Cyst contents

- 1-breakdown products of degenerating epithelial cell and inflammatory cell and connective tissue components.
- 2-serum proteins. Compared with serum the fluid contain higher level of immunoglobulin which probably reflect local production of plasma cells in the capsule .
- 3Water and electrolytes
- 4-Cholesterol crystals

Cyst expansion

- Cysts expansion is dependent on osteoclastic resorption of surrounding bone. activated at sites of resorption by mediators. The cytokines interleukin-1 and interleukin-6 (IL-1, IL-6) tumor necrosis factor and prostaglandin E2 are key mediators in cyst expansion.

- • Activated osteoclast attached to the bone surface and release acids resulted in de mineralization. The organic matrix is then degraded by matrix metalloproteinase MMP's, collagenases, and lysosomal proteases
- • Bone resorption is followed by cyst expansion
- • Cyst contents are hypertonic. The wall acts as a semi permeable membrane and retains the osmotically active molecules in the lumen creating an **osmotic gradient**. Water moves into the lumen along the gradient increasing the hydrostatic pressure in the cyst leading to enlargement.

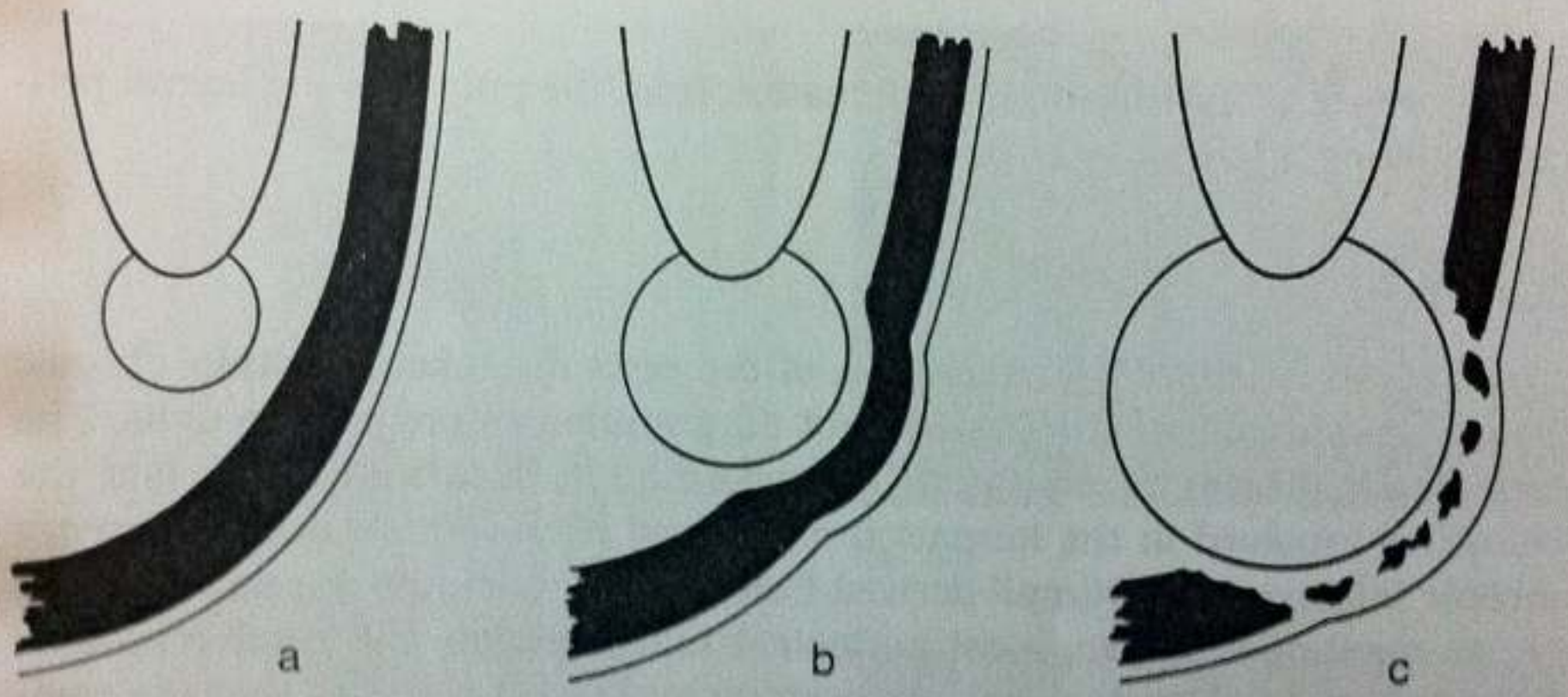

Fig.
proc
thin

layers of new bone by the overlying periosteum. As the cyst enlarges and causes bone resorption centrally, increments of new subperiosteal bone are laid down to maintain integrity of the cortex, producing a bony-hard expansion. However, the